

---

## ALICAM Ambulatory Light-based Imaging Report

---

Patient Name: 10  
Patient Age: 8614  
Patient ID:  
Owner Name  
Interpreting Veterinarian: Jill Pomrantz, DVM, DACVIM (SAIM)  
Affiliation: Infiniti Medical  
Referring Veterinarian:  
Referring Clinic:  
Procedure Date: Tuesday, November 17, 2015  
Capsule SN: K0677.0080

---

First Gastric Image: Time: 0:01:10, Frame: 148  
First Duodenal Image: Time: 11:19:14, Frame: 24059  
First Cecal Image: Time: 12:57:52, Frame: 27185  
Gastric Transit Time: 11:18:04  
Small Bowel Transit Time: 1:38:38

---

### Clinical History:

Previous history of splenectomy/liver lobe removal for hematomas (3 years ago), also cutaneous MCTs years ago. O noticed melena 4 days ago, collapsed yesterday with PCV 13%/TP 3.0. No previous meds.

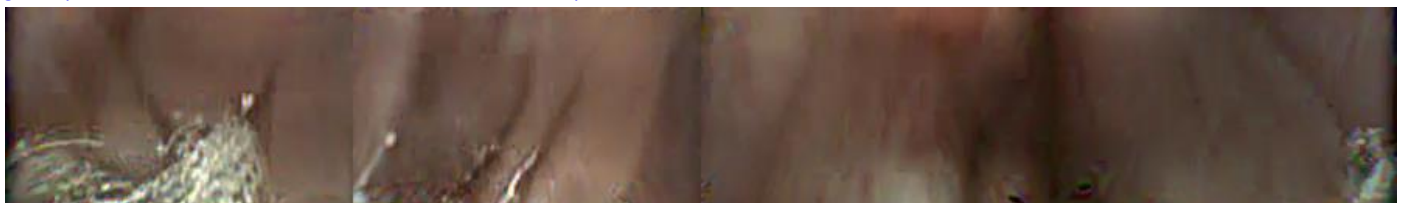### Findings:

Image 1 (Frame Number: 125, Transit Time: 0:01:04)




Normal esophagus

Image 2 (Frame Number: 148, Transit Time: 0:01:10)



First gastric image

Image 3 (Frame Number: 1186, Transit Time: 0:25:49)



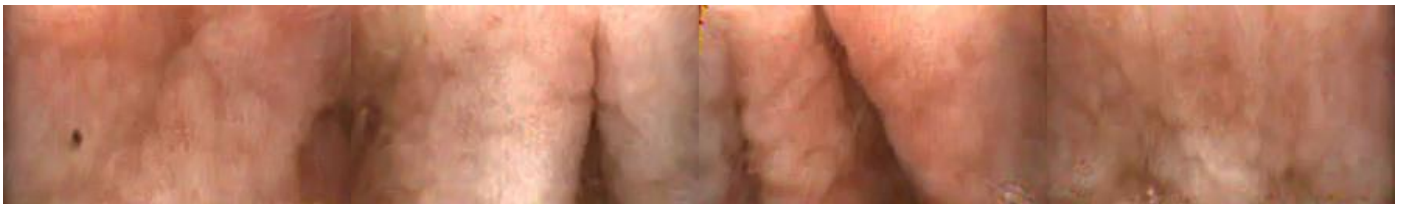Normal gastric mucosa

Image 4 (Frame Number: 6410, Transit Time: 2:13:06)



Foreign material with hair

Image 5 (Frame Number: 9583, Transit Time: 4:04:06)



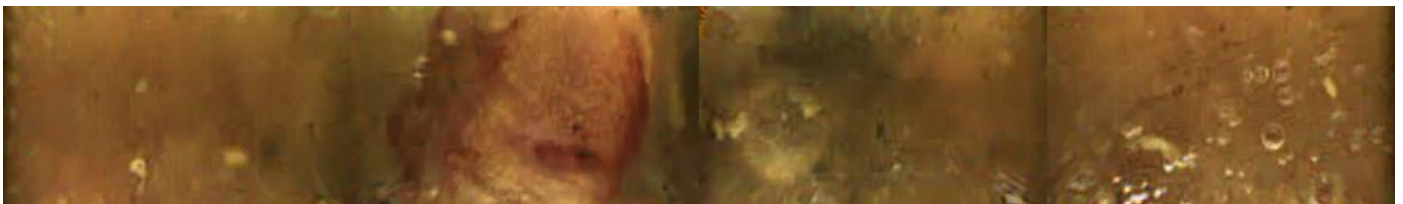
Irregular gastric mucosa

Image 6 (Frame Number: 10444, Transit Time: 4:28:52)



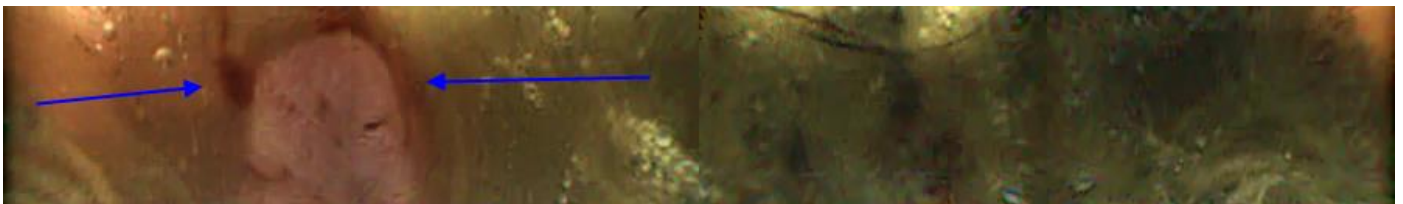
Gastric hemorrhage

Image 7 (Frame Number: 11557, Transit Time: 5:14:46)



Irregular gastric mucosa with hemorrhage

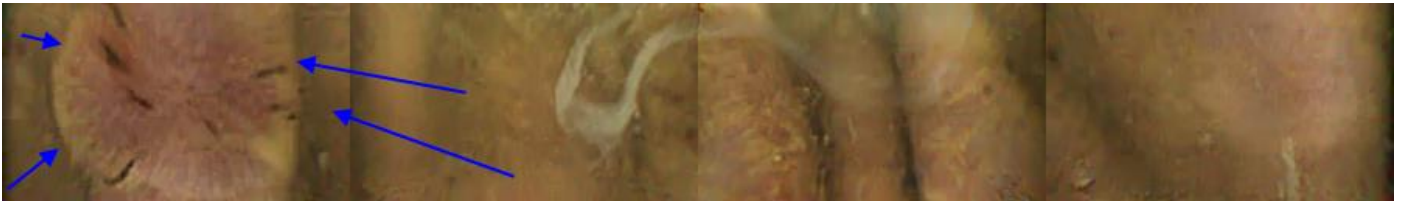
Image 8 (Frame Number: 16696, Transit Time: 7:48:16)



First lesion - irregular mucosa or mass with surrounding hemorrhage



Image 9 (Frame Number: 20624, Transit Time: 9:26:26)



Second mass-like lesion, polypoid appearance

Image 10 (Frame Number: 21185, Transit Time: 9:45:34)



Irregular mucosa with hemorrhage

Image 11 (Frame Number: 21596, Transit Time: 9:59:42)




Irregular mucosa with evidence of previous hemorrhage

Image 12 (Frame Number: 22793, Transit Time: 10:42:35)



Irregular mucosa with hemorrhage

Image 13 (Frame Number: 23095, Transit Time: 10:51:57)



Third mass-like lesion

Image 14 (Frame Number: 23216, Transit Time: 10:55:28)



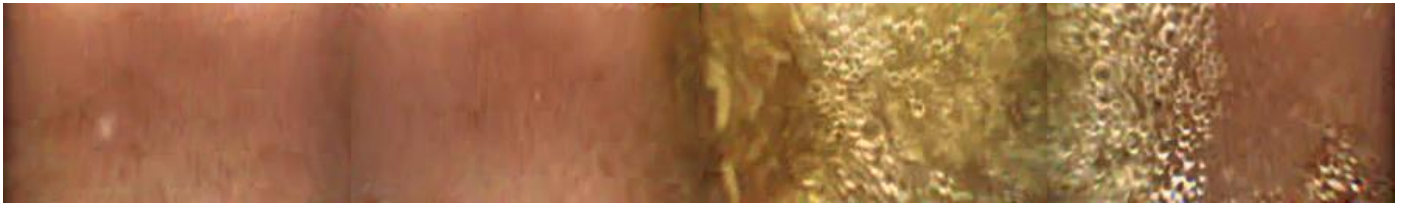Suspect hematoma

Image 15 (Frame Number: 23824, Transit Time: 11:13:07)



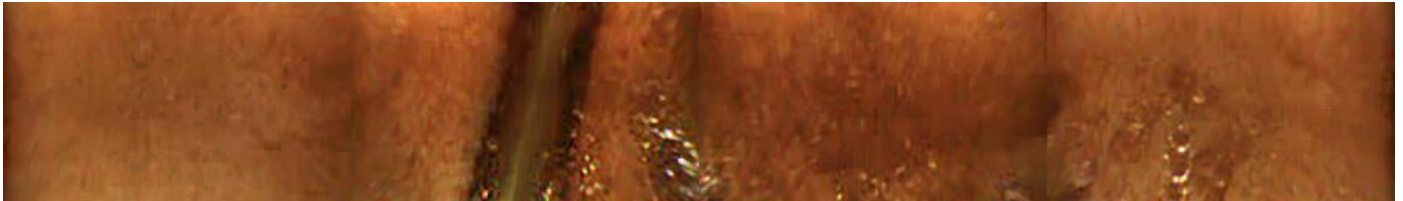
Suspect hematoma

Image 16 (Frame Number: 24059, Transit Time: 11:19:14 ( Small Bowel Time 0:00:00 (00%) ))



First duodenal image

Image 17 (Frame Number: 25691, Transit Time: 12:00:08 ( Small Bowel Time 0:40:53 (52%) ))



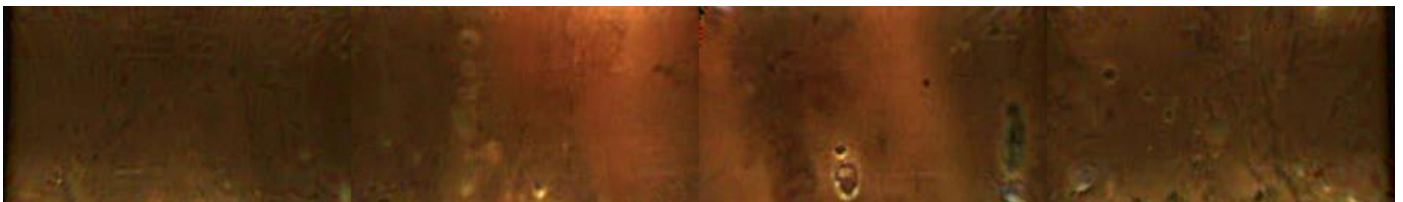Blade of grass in small intestine

Image 18 (Frame Number: 27185, Transit Time: 12:57:52 ( Small Bowel Time 1:38:37 ))



First colonic image

Image 19 (Frame Number: 27668, Transit Time: 15:00:39)



Final image

Finding Summary and Recommendations:

There are 27668 images in 15h39s of study time.

The esophagus is normal.

When the capsule first enters the stomach, the mucosa is normal. As the capsule passes through the stomach, the mucosa becomes progressively irregular and small hemorrhages can be seen at multiple sites (both active and previous). There is no one discrete mass, but 3 suspicious mass-like areas are identified. The first lesion has irregular mucosa with surrounding hemorrhage. The second lesion has a polypoid in appearance. The third lesion is mostly obscured by dark material that is likely a hematoma. This lesion can be seen very briefly when the material clears.

There is a small amount of foreign material or ingesta mixed with hair that is likely not significant

There is delayed gastric emptying and the capsule remains in the stomach for 11+ hours.

There is some dark fluid in the small intestine, but the mucosa is visible and is normal.

The colon is obscured by feces. The visible mucosa is normal.

Recommendations:

If the patient is stable for anesthesia, endoscopy is recommended to examine the abnormal areas seen on this examination and obtain biopsies.

Continuation of gastroprotectants is also indicated (omeprazole 1mg/kg PO q12, sucralfate 1g PO q8h) +/- metoclopramide 0.2-0.4mg/kg PO q8-12h.

Signature: *Jill Pourantz* Date: 11/17/2015

Contact Information: alicamsupport@infinitemedical.com (650) 327-5000